

Case Report

Perforated epiphrenic diverticulum with secondary septic pleuritis in two horses

M. GONZALEZ*, T. M. SWOR[†] AND M. T. HINES

Washington State University, Department of Veterinary Clinical Sciences, PO Box 647060, Pullman, Washington 99164-7060, USA.

Keywords: horse; equine; oesophageal diverticulum; thoracic; oesophagitis; muscular hypertrophy

Summary

This report describes 2 cases of oesophageal diverticula in horses in which the perforation of the diverticulum led to septic pleuritis. Both cases presented as emergencies with the clinical complaint of colic and had evidence of endotoxic/septic shock. Due to its rareness and its tendency to masquerade as a variety of more common conditions, the recognition and management of intrathoracic oesophageal perforation in horses can be difficult, and neither of the horses presented here had clinical signs consistent with oesophageal obstruction upon presentation.

The cases reported here illustrate the importance of a complete physical evaluation, and of taking into consideration the thorax as a source of colic signs and systemic inflammatory response syndrome in horses.

Introduction

Oesophageal disorders in horses are relatively common, obstruction being the most frequently reported abnormality (Feige *et al.* 2000). In horses, diverticula are an occasional cause of oesophageal dysfunction that usually occur in the cervical portion of the oesophagus (Aanes 1976; Hackett *et al.* 1978; Frauenfelder and Adams 1982; Vrins *et al.* 1983; MacDonald *et al.* 1987; Craig *et al.* 1989; Harrison and Cartee 1990; Ford *et al.* 1991) and rarely, in the thoracic portion (van Wuijckhuise-Sjouke 1983; Ford *et al.* 1991). Swain *et al.* (2004) reported a unique case of a diverticulum in the distal intra-abdominal oesophagus. With rare exceptions (van Wuijckhuise-Sjouke 1983), oesophageal diverticula in horses have been associated with chronic intermittent obstruction and, if localised in the cervical portion, with a neck swelling that increases in size after eating (Aanes 1976; Hackett *et al.*

1978; Frauenfelder and Adams 1982; MacDonald *et al.* 1987; Craig *et al.* 1989; Harrison and Cartee 1990; Murray and Gaughan 1993). Oesophageal diverticula are usually diagnosed by contrast radiography and endoscopy (Ford *et al.* 1991). Repair of an oesophageal diverticulum in the horse generally includes diverticulectomy or inversion of the mucosal sac, followed by closure of the defect in the *tunica muscularis* (Craig *et al.* 1989; Harrison and Cartee 1990). This report describes 2 cases of oesophageal diverticula in horses with unusual features due to the location of the diverticula, the clinical presentation, the perforation of the diverticula with secondary septic pleuritis, and the concurrence of idiopathic muscular hypertrophy of the oesophagus (IMHO).

Case details

Case 1

History

A 21-year-old Appaloosa-Paint mare used for pleasure riding presented to the Veterinary Teaching Hospital (VTH), Washington State University (WSU), Pullman, with a history of acute colic signs and progressive depression, anorexia, fever and muscle fasciculations of about 12 h duration. On the morning of presentation, before eating her feed, the mare was reportedly normal. About 1 h later, she was shivering, listless and exhibiting bruxism. A physical examination performed by a local veterinarian was unremarkable (rectal temperature 37.7°C; heart rate 36 beats/min; mucous membranes pink with a capillary refill time of 2 s; normal to decreased gastrointestinal sounds) except for a mild lethargy and possible ataxic gait at a walk. A rectal palpation revealed no abnormal findings. A complete blood cell count and biochemistry panel revealed a mild leucopenia (WBC 4.6 x 10⁹/l; rr 5.8–9.4 x 10⁹/μl) with no other abnormalities. The mare improved after administration of 450 mg flunixin meglumine but in the late afternoon the horse became depressed, febrile (39.9°C), tachycardic (72 beats/min) and mildly colicky. Her mucous membranes were bright red.

*Author to whom correspondence should be addressed. [†]Present address: Department of Large Animal Clinical Sciences, Texas A&M University, 4475 TAMU, College Station, Texas 77843-4475, USA.

Flunixin meglumine paste (450 mg) was given orally and the mare was referred to the VTH. The owner reported no previous history of clinical problems except for an episode of exertional rhabdomyolysis 6 months previously.

Clinical findings

At presentation, the mare was quiet, responsive, and appeared weak. Her body condition score was 7/9. She was sweating and had generalised muscle fasciculations. Her temperature was 37.7°C, heart rate 80 beats/min and respiratory rate 36 breaths/min with mildly increased respiratory effort. Her mucous membranes were dark red with a toxic line. She was estimated to be 10% dehydrated based on tacky mucous membranes, a capillary refill time of 3–4 s, cool extremities, weak peripheral pulses and a prolonged skin tent. Thoracic auscultation was unremarkable and gastrointestinal sounds were normal to increased.

Haematology

A complete blood count revealed erythrocytosis (PCV 58%, rr 30–48), normal total protein (67 g/l, rr 56–79) and fibrinogen levels (4 g/l, rr 1–4 g/l), thrombocytopenia (platelets $65 \times 10^9/l$, rr 102–200 $\times 10^9/l$), and leucopenia ($2.5 \times 10^9/l$, rr 5.8–9.4 $\times 10^9/l$). The leucogram was characterised by severe neutropenia with a marked left shift (bands 500/ μ l, rr <100/ μ l; mature neutrophils 500/ μ l, rr 2300–8600/ μ l) and marked toxic changes. A biochemistry panel revealed elevated creatinine (46 g/l, rr 7–15 g/l).

Case management

The haematological abnormalities, presence of a toxic line, fever, tachycardia/tachypnoea, lethargy, and evidence of poor peripheral perfusion and dehydration were most likely indicative of septic/endotoxic shock. A nasogastric tube passed without difficulty and yielded no gastric reflux. After placing 2 i.v. catheters, i.v. fluid-therapy was initiated. Rectal palpation and abdominal fluid cytology were normal. A brief abdominal ultrasonography revealed minimal amounts of free abdominal fluid and several moderately distended loops of small intestine with adequate motility on the ventral abdomen. Initial fluid-therapy consisted of 2 l of hypertonic saline 7.2% and 30 l lactated Ringer's as a bolus after which the horse was observed urinating and her PCV and total protein decreased to 47% and 37 g/l, respectively. At that time, the rate of i.v. fluids was decreased to 2 l/h lactated Ringer's. Defaecation was also observed while receiving the i.v. fluids and faeces had a normal appearance. Within a few hours, her mucous membranes turned purplish and the mare began showing signs of increased respiratory effort with a respiratory rate of 54 breaths/min, and colic signs (pacing, rolling and pawing). She received 500 mg of flunixin meglumine i.v. and was tubed again obtaining no net reflux. With a poor prognosis, exploratory laparotomy was offered to the owner in an attempt to find the source of the

endotoxic/septic shock. However, the rapid deterioration of the patient precluded that option and humane euthanasia was performed.

Post mortem examination and histopathology

Gross *post mortem* examination revealed an oesophageal diverticulum with perforation, severe oesophageal smooth muscle hypertrophy, chronic ulcerative oesophagitis, and severe fibrinopurulent pleuritis. Approximately 3–4 l of turbid, green-brown fluid with fibrin and small fragments of feed material were present free in the thoracic cavity. Sheets and tags of fibrin associated with feed material were attached to all pleural surfaces. The dorsal oesophagus had an approximately 9 x 5 cm ovoid, 3–4 cm deep, dilated, thin walled outpocketing just cranial to the oesophageal hiatus. A 1.5 cm perforation with thin ragged edges (partially incorporating a smooth edged ulcer) was present within the dilated area (**Fig 1**). The mucosal surface of the dilated area had multiple smooth edged linear erosions/ulcers ranging from 1.5–5 cm long by 0.7 cm wide (**Fig 2**). The *tunica muscularis* of the mid to caudal thoracic oesophagus was severely thickened (35 mm) (**Fig 3**).

The histopathological diagnoses were: ulcerative, necrotising oesophagitis with perforation and mural fibrosis, chronic diverticulum formation with separation of the *tunica muscularis* (pulsion diverticulum), and diffuse fibrinous pleuritis and pleural fibrosis. The margin of the perforated ulcer was necrotic and composed of fibrin, bacteria, cellular debris and plant material. The margin of the *tunica muscularis* at the origin of the diverticulum was rounded and overlaid with fibrosis and granulation tissue. The interlobular septa and thoracic side of the diaphragm were covered by multiple layers of granulation tissue. The deep layer was mature with no plant material or bacteria. The outer layer was composed of fibrin, cellular debris, clumps of bacteria and plant material and had little vascularisation or organisation. This layer arrangement indicated a possible initial episode of low-grade, localised pleuritis at least 10 days prior to presentation to the VTH that was resolving when the perforation occurred. The dissecting necrosis and fibrosis in the wall of the oesophagus suggested that ulcerations may have led to partial migration of bacteria through the wall at an early time that could have initiated the first episode of pleuritis without involving direct perforation. No significant lesions were found in the abdomen.

Case 2

History

A 4-year-old Friesian gelding was admitted to the VTH, for an evaluation of acute colic of 5 h duration. On the night of presentation, the owner fed the horse as usual, and half an hour later found the animal breathing hard and showing signs of abdominal pain. Nasogastric intubation yielded no reflux. The horse received 200 mg xylazine followed 1 h later by 200 mg xylazine, 600 mg flunixin meglumine, 60 mg

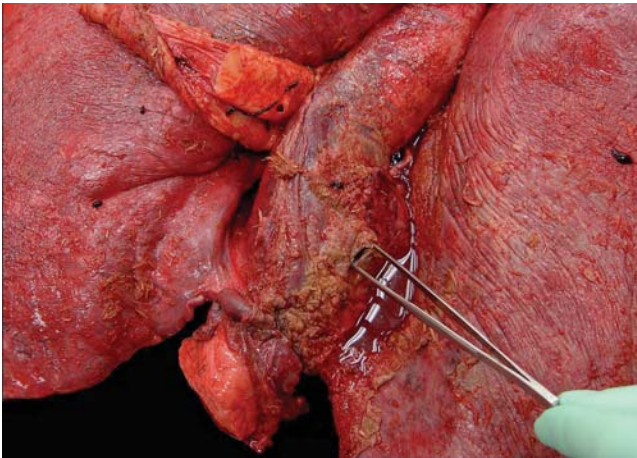


Fig 1: Case 1: Post mortem photograph of an epiphrenic oesophageal diverticulum showing a full-thickness perforation of the oesophageal wall. Note also the gross feed material contamination of the serosal surfaces.

butorphanol, and 190 mg N-butylscopolammoniumbromide (Buscopan)¹, with little effect, and was referred to the VTH.

The horse was evaluated twice during the previous 2 weeks at the VTH for acute choke, the last episode occurring one week before the current visit. The day before the first episode of choke, the horse was colicky, restless and inappetent. That day the referring veterinarian gave mineral oil by nasogastric tube and felt increased resistance to the passage of the tube. The following morning the horse was found choked and haematology performed at WSU revealed a mild neutrophilia ($11.2 \times 10^9/l$, rr $2.3\text{--}8.6 \times 10^9/l$) with a mild regenerative left shift ($143 \text{ bands}/\mu l$, rr $<100/\mu l$). The day before the second episode of choke, the horse developed a fever and was placed on trimethoprim-sulphamethoxazole (20 mg/kg bwt , *per os*, q. 12 h) and omeprazole (4.4 mg/kg bwt , *per os*, q. 24 h). In both choke episodes, physical

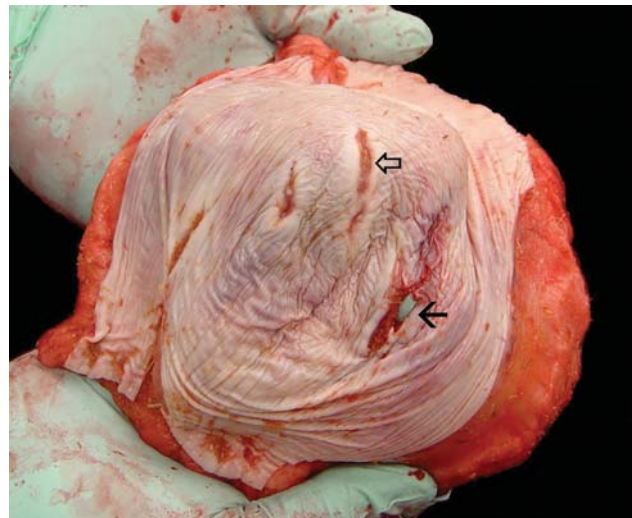


Fig 2: Case 1: The lining of the oesophageal diverticulum presented several areas of linear ulceration, as depicted by the open arrow. Note also that the perforation occurred at one of these ulcerated areas (black arrow).

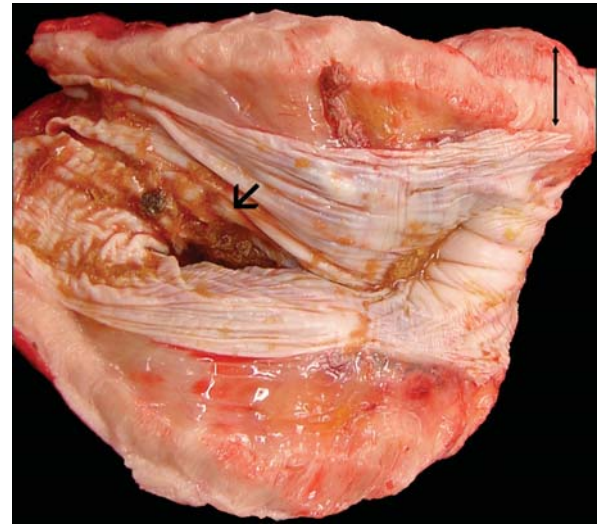


Fig 3: Case 1: Longitudinal section of the distal oesophagus showing the entrance to the diverticulum (black arrow) and the marked thickening of the oesophageal wall due to idiopathic muscular hypertrophy (double arrow).

examinations at the VTH were unremarkable and endoscopic examinations revealed mild gastric ulcers and an oesophageal diverticulum at 170 cm from the nose, very close to the cardia (**Fig 4**). The oesophageal mucosa contained in the diverticulum had several small areas of superficial ulceration. The owner was instructed to feed slurries of pellets from an elevated position and have periodical re-evaluation of the diverticulum via endoscopy.

Clinical findings

On arrival at the VTH the patient was depressed, sweating and had muscle fasciculations. The animal was trying to lie down, and 10 mg butorphanol i.v. was given in order to complete the initial work-up. His body condition score was estimated as 7/9. Rectal temperature was 40.1°C , heart rate 100 beats/min, and respiratory rate 68 breaths/min with an increased respiratory effort. Mucous membranes were pink with a capillary refill time $<2 \text{ s}$. Gastrointestinal sounds were absent in all

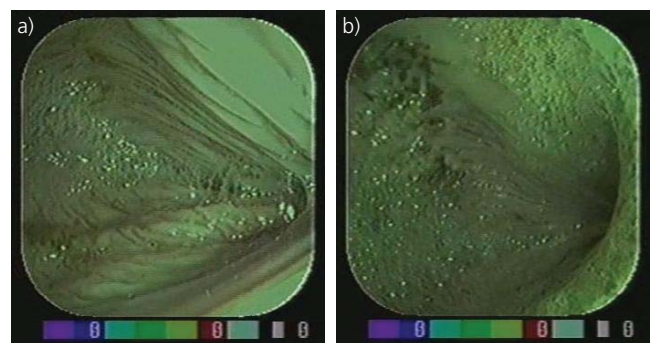


Fig 4: Two different endoscopic views of the distal oesophagus of the horse in Case 2, showing marked dilatation of the oesophageal lumen at the level of the diverticulum. Note a more normal diameter of the oesophageal lumen at the most distal part of the diverticulum.

quadrants and bilateral dull lung sounds were present on the ventral thorax. Upon passage of a nasogastric tube without difficulties no reflux was obtained. Rectal examination revealed a moderately gas distended large colon.

Haematology

Haematology revealed a PCV of 51% (rr 30–48), a total protein of 67 g/l (rr 56–79 g/l), fibrinogen levels of 3 g/l (rr 1–4 g/l), mild leucopenia (WBC $4.8 \times 10^9/l$, rr: $5.8\text{--}9.4 \times 10^9/l$) with a mild left shift (240 bands/ μ l, rr <100/ μ l) and few toxic changes, and a moderate hyperglycaemia (1.79 g/l, rr 0.66–1.18 g/l).

Case management

Peritoneal fluid analysis revealed a mild elevation in the leukocyte count ($5.5 \times 10^9/l$, rr < $2.5 \times 10^9/l$), a protein of 22 g/l (rr <30 g/l), and no cytological abnormalities. Based on the degree of discomfort and the abnormal rectal examination, and because resolution of the abdominal colic was considered the clinical priority despite a possible concurrent respiratory problem, it was decided to take the horse to surgery for an exploratory laparotomy. Prior to surgery, the horse received i.v. fluids (1 l hypertonic saline 7.2% and 15 l lactated Ringer's as a bolus), antimicrobials (potassium penicillin 22,000 iu/kg bwt, i.v. and gentamicin 6.6 mg/kg bwt, i.v.) and flunixin meglumine (0.5 mg/kg bwt, i.v.). Upon exploration of the abdominal cavity, a right dorsal displacement of the large colon was identified, along with a moderate gas-distension of the small intestine and caecum. During anaesthesia the patient remained markedly hypotensive and hypoxic, even after relieving the gas-distension of the intestine. Because there were concerns about a possible respiratory disorder in addition to his gastrointestinal lesion, a thoracic ultrasound was requested while performing the celiotomy. The ultrasonographic examination revealed bilateral pleural effusion and multiple contour irregularities on the visceral pleura. Ultrasound-guided thoracocentesis yielded approximately 3 l of serosanguineous fluid from each hemithorax that contained multiple fibrin clots. Food material within the pleural fluid was not grossly seen. Cytological evaluation of the fluid was consistent with a suppurative inflammatory response with high numbers of a mixed population of intracellular and extracellular bacteria. The WBC counts of the fluid from the right and left hemithorax were $2.53 \times 10^9/l$ and $6.93 \times 10^9/l$, respectively. Total protein was 51 g/l on both sides. After moving the horse to the recovery stall, the horse entered into respiratory and cardiac arrest. Attempts to resuscitate the horse were unsuccessful and the horse died.

Post mortem examination and histopathology

Gross examination revealed a severe fibrinous pleuritis with ingesta, a distal oesophageal pulsion diverticulum with perforation, severe smooth muscle hypertrophy of the distal oesophagus and severe oesophagitis. The thoracic cavity

contained several litres of cloudy, dark, yellow fluid. Large mats of fibrin mixed with large amounts of feed material were adhered circumferentially to the distal oesophagus and serosal surfaces of the thorax. The wall of the distal third of the oesophagus was approximately 3.0 cm thick due to smooth muscle hypertrophy and large amounts of oedema. Approximately 20 cm of the distal oesophagus on the pleural side of the diaphragm was eccentrically dilated to approximately twice the normal diameter. An approximately 6.0 cm long tear with jagged edges was within the diverticular mucosa and extended nearly to the diaphragm. Adjacent to the tear, a 10 cm long, V-shaped area of the *tunica muscularis*, with the apex pointing orad, was separated with only the mucosa remaining. The torn edges of the *tunica muscularis* were tattered and dark red due to small amounts of haemorrhage suggestive of a recent acute traumatic event. Large amounts of oedema were within the wall of the oesophagus throughout this area. An approximately 12 x 6 cm area of the mucosa of the diverticulum was ulcerated. Several areas of the distal oesophagus, with a diameter from 1.0–3.0 cm, were ulcerated. Histopathological evaluation of the diverticulum revealed that there was granulation tissue of at least 7 days old replacing the outer layer of the *tunica muscularis* at the site of the diverticulum. The pleuritis was an acute change attributed to the rupture of the oesophagus, and had probably been present for less than 24 h. The outer layer of the distal *tunica muscularis* was severely thickened to approximately 1.5 cm by histologically normal myocytes (smooth muscle hypertrophy). Gross and histological evaluation of the abdomen revealed no abnormalities other than the expected changes after undergoing an exploratory laparotomy and enterotomy of the pelvic flexure.

Discussion

The oesophagus of adult horses varies in length from 125–200 cm, and consists of cervical, thoracic and abdominal parts, with the cervical part comprising over 50% of the total length (Stick 1999). The wall of the oesophagus is composed of 4 layers: a fibrous layer (*tunica adventitia*), muscular layers (*tunica muscularis*), a submucosal layer, and a mucous membrane (*tunica mucosa*). The muscular layers are striated from the pharynx to the base of the heart, where they gradually blend into smooth muscle (Stick 1999; Fubini 2002).

Regarding mechanisms of formation, 2 types of oesophageal diverticula are described: pulsion and traction. Pulsion diverticula (or false diverticula) are the most commonly reported in man and horses and consist of mucosal and submucosal herniations through acquired defects in the *tunica muscularis* of the oesophagus. They are the result of local trauma or acute changes in intraluminal pressure, which results in separation of the muscularis and subsequent herniation of the mucosa (Aanes 1976; Frauenfelder and Adams 1982; Vrins et al. 1983; MacDonald et al. 1987; Harrison and Cartee 1990; Costantini et al. 2004; Nutter and Ball 2004). Some pulsion diverticula may also develop

congenitally (Ford *et al.* 1991). Pulsion diverticula usually have a flask shape with a small neck. Because they have a tendency to fill with feed material, ultimately leading to oesophageal obstruction and rupture, surgical repair is indicated (Hackett *et al.* 1978; Harrison and Cartee 1990; Ford *et al.* 1991; Stick 1999). Traction diverticula (or true diverticula) are much less common and result from perioesophageal scarring that exerts traction on segments of the oesophageal wall, which results in tenting of the wall of the oesophagus. A traction diverticulum contains all of the wall layers and therefore, tends to transmit normal peristalsis. They usually have a wide opening with a shallow body, and rarely cause clinical signs (MacDonald *et al.* 1987; Harrison and Cartee 1990; Ford *et al.* 1991; Stick 1999; Costantini *et al.* 2004; Nutter and Ball 2004).

Depending on their location, oesophageal diverticula are classified into 3 types: Zenker's, parabronchial and epiphrenic diverticula (Costantini *et al.* 2004; Nutter and Ball 2004). Zenker's diverticula are pulsion diverticula at the pharyngo-oesophageal junction. Parabronchial diverticula are traction diverticula and result of a chronic inflammatory process starting from the mediastinal lymph nodes. Epiphrenic diverticula are pulsion diverticula that occur at the distal oesophagus, just cranial or above the oesophageal hiatus (Cantù *et al.* 2003; Costantini *et al.* 2004; Nutter and Ball 2004). Epiphrenic diverticula are believed to be caused by an underlying motility disorder of the oesophagus, such as achalasia, that results in abnormal intraluminal pressure and the pushing of the oesophageal mucosa through focal weaknesses of the muscular wall. In man, the most common type is Zenker's diverticulum, followed by epiphrenic diverticulum (Cantù *et al.* 2003). Intrathoracic diverticula in horses are rarely reported (van Wuijckhuise-Sjouke 1983; Ford *et al.* 1991). In one case, the colt presented with recurrent episodes of choke and the intrathoracic diverticulum was successfully repaired by thoracotomy and diverticulectomy (Ford *et al.* 1991). In the second reported case of intrathoracic diverticula, no clinical signs were noted prior to the oesophageal perforation and the horse was subsequently subjected to euthanasia (van Wuijckhuise-Sjouke 1983). In man, complications of epiphrenic diverticula include obstruction, bezoar formation, perforation, gastrointestinal bleeding and cardiac arrhythmia (Nutter and Ball 2004).

The colic signs soon after eating present in the 2 cases reported here may resemble the most common clinical condition of oesophageal obstruction. However, in these cases, the absence of nasal discharge and increased salivation together with the ability to pass a stomach tube ruled out the presence of oesophageal obstruction. In a retrospective study of 34 horses with oesophageal obstruction by Feige *et al.* (2000), there was only one case of oesophageal diverticulum (location was not specified). In the series of 61 horses with oesophageal disorders reported by Craig *et al.* (1989), only 5 horses had an oesophageal diverticulum and all of them were localised at the cervical oesophagus. In none of these 5 cases was there perforation of the diverticula. The median age of these horses was 12 years (range 2–13 years) and the median

duration of clinical signs ranged from 2 months–11 years. All of these 5 horses had clinical signs related to the diverticulum characterised by intermittent obstructions and the presence of a cervical mass that was evident especially after eating. In the same report, of the 61 horses with oesophageal disorders, 11 had a perforation of the oesophagus, all of them extrathoracic. The most common aetiological factors were traumatic nasogastric intubation, prior feed impaction, and cervical neck trauma. None of these 11 cases of oesophageal perforation was associated with a diverticulum.

These cases of oesophageal disorders (Craig *et al.* 1989) contrast with the 2 cases presented here in several ways. Both of the horses presented in this report had a perforated intrathoracic diverticulum, were referred for evaluation of colic, and presented clinical signs of endotoxaemia/sepsis upon initial examination at the VTH. Also, Case 1 had no history of choke, dysphagia or any other clinical signs that could be attributed to oesophageal disorder; and Case 2 had only a 2-week history of recurrent choke.

In horses, oesophageal perforation usually happens in the cervical region in response to traumatic or prolonged nasogastric intubation, external neck trauma, necrosis secondary to food impaction, and/or rupture of a lesion such as an impacted diverticulum or oesophageal ulcer (Craig *et al.* 1989; Dechant *et al.* 1998; Benders *et al.* 2004). Common clinical signs are subcutaneous emphysema, cellulitis, endotoxaemia/sepsis and infection of the pleural spaces (Craig *et al.* 1989; Dechant *et al.* 1998). In man, thoracic oesophageal perforation has traditionally been considered a life-threatening event with mortality rates of 4–40% and even higher (Vogel *et al.* 2005). To the best of our knowledge, the scarce number of documented cases of intrathoracic oesophageal perforations in horses and cows (van Wuijckhuise-Sjouke 1983; Dechant *et al.* 1998; de Vlieghe *et al.* 2001) were all fatal and no treatment was attempted.

One of the reasons for intrathoracic oesophageal perforations being a catastrophic event in large animals is that by the time clinical signs become obvious, pleuritis and endotoxaemia/sepsis are too severe. Our research in the equine veterinary literature on cases of perforated intrathoracic diverticula yielded a single case report written in Dutch (van Wuijckhuise-Sjouke 1983). The author described the case of an 8-year-old Haflinger mare that was evaluated for lethargy, tachycardia, tachypnoea, fever, hyperaemic mucous membranes and colic. Despite medical treatment, the pony rapidly deteriorated and died after a few hours. *Post mortem* examination revealed a dilatation of the oesophagus above the heart, 20 cm long and 15 cm deep, and generalised pleuritis. The musculature of the oesophagus caudal to the dilatation was markedly hypertrophic over a distance of 20 cm and no abnormalities were found in the tissues surrounding the oesophagus. This case and Case 1 are especially unusual because at no time had these horses showed clinical signs associated with an oesophageal disorder; neither had they a previous history suggestive of an oesophageal disorder. Therefore, the perforation of the diverticulum appeared to be a spontaneous event.

The lack of clinical signs associated with epiphrenic diverticula is not uncommon in man in whom the majority of the epiphrenic diverticula are asymptomatic (Costantini *et al.* 2004; Nutter and Ball 2004). More unusual is the apparently spontaneous perforation of the diverticula. Cantù *et al.* (2003) reported the case of a spontaneous perforation of an epiphrenic diverticulum in a human patient with unknown achalasia. In man, spontaneous perforation of the oesophagus (also known as Boerhaave's syndrome) is a rare occurrence (Cantù *et al.* 2003) and the most commonly affected site is the lower third of the oesophagus (Hill *et al.* 2003). To our knowledge, this syndrome has not been reported in veterinary medicine.

It is also interesting to note that idiopathic muscular hypertrophy of the oesophagus (IMHO) was present in the 2 cases presented here and the case reported by van Wuijckhuise-Sjouke (1983). Recently, Benders *et al.* (2004) reviewed the medical records of 31 horses with IMHO and none of these horses had an oesophageal diverticulum. According to Benders *et al.* (2004), IMHO is not a rare occurrence and affects the distal oesophagus of mostly mature horses, with no sex or breed predilection. In the majority of cases, IMHO is a coincidental finding at *post mortem* examination. As in man, hypertrophy is usually confined to the smooth, circular muscle layer with a lesser involvement of the longitudinal layers of the *tunica muscularis externa* (Benders *et al.* 2004). In these 31 cases of IMHO, the oesophageal lumina showed no detectable obstructive stenosis; furthermore, 20 of the 31 patients were admitted for colic and difficulties associated with passing a nasogastric tube into the stomach were not found. Occasionally, IMHO is seen in combination with hypertrophy of various other muscular sites of the gastrointestinal tract, especially the ileum (Benders *et al.* 2004), but this was not observed in the cases reported here.

The diagnosis of functional oesophageal disorders requires neuromuscular evaluation by manometry, electromyography, and muscle or nerve biopsies (Craig *et al.* 1989; Costantini *et al.* 2004). To the authors' knowledge, evaluation of oesophageal motility has not been reported in horses with either IMHO or oesophageal diverticula. Therefore, it is unknown whether a primary oesophageal motility disorder of the distal oesophagus is associated with these oesophageal disorders. In man a primary oesophageal motility disorder is the underlying cause of most epiphrenic diverticula (Nehra *et al.* 2002; Tedesco *et al.* 2005). Identified motor abnormalities associated with epiphrenic diverticula in humans include: achalasia, diffuse oesophageal spasm, hypertensive lower oesophageal sphincter, 'nutcracker' oesophagus and nonspecific oesophageal motor disorder. Of these, achalasia is the most common disorder associated with epiphrenic diverticulum (Nehra *et al.* 2002). The major finding in humans affected with oesophageal achalasia is increased tone of the lower oesophageal sphincter with inability of the sphincter to relax completely (Benders *et al.* 2004). In horses, IMHO may be a manifestation of a motility disorder that has not yet been characterised. Although the case series by Benders *et al.* (2004) do not support an association between oesophageal

diverticulum and IMHO, the concurrence of both disorders in the 2 cases presented here and in the case reported by van Wuijckhuise-Sjouke (1983) opens the possibility of a connection between IMHO and epiphrenic diverticula.

The 2 horses of this report presented as emergencies with the clinical complaint of colic and had evidence of endotoxaemic/septic shock. After retrospective evaluation of the cases presented here, the authors acknowledge that an initial thorough evaluation of the thorax, which may have precluded or delayed surgery in Case 2, was not performed and that the diagnostic efforts to determine the source of the pain and systemic inflammatory response syndrome were mostly focused to the abdomen. In Case 1, thoracic visceral pain and endotoxaemia were the likely source of the signs of colic reported clinically, while the contribution of these to the colic signs in Case 2 is uncertain due to the concurrent large colon displacement. Although clinical signs of endotoxaemia are usually easy to recognise, determining the underlying cause for the development of endotoxaemia may be a challenging task (Moore and Barton 2003). Due to its rareness and its tendency to masquerade as a variety of more common conditions, the recognition and management of intrathoracic oesophageal perforation in horses can be difficult. The cases reported here accentuate the importance of a complete physical evaluation and the importance of taking into consideration the thorax as a source of colic signs and systemic inflammatory response syndrome in horses.

In man, oesophageal diverticula may complicate nasogastric tube placement with entrapment of the tip of the tubing within the diverticulum. This complication of tube placement may lead to increased risk of aspiration and perforation (Nutter and Ball 2004). Aanes (1976) reported one horse with a cervical oesophageal diverticulum in which the tube passed with difficulty or did not pass beyond the thoracic inlet. In Case 2, the reported difficulty passing the nasogastric tube may have contributed to the tissue trauma present at the diverticulum as evidenced by the gross and histological findings. Thus, although the presence of oesophageal diverticula may not impair the passage of a nasogastric tube, blind passage of nasogastric tubes should be avoided or performed carefully in patients with known oesophageal diverticula.

In conclusion, this report emphasises the importance of considering oesophageal perforation as a differential diagnosis for colic and endotoxaemia, independently of the presence or lack of historical or clinical evidence of oesophageal disorder. Also, in horses, the role of a primary oesophageal motility disorder of the distal oesophagus in the development of either IMHO or oesophageal diverticula remains speculative and deserves further investigation.

Manufacturer's address

¹Boehringer Ingelheim GmbH, Ingelheim, Germany.

References

Aanes, W.A. (1976) The diagnosis and surgical repair of diverticulum of the oesophagus. *Proc. Am. Ass. equine Practns.* **21**, 211-222.

- Benders, N.A., Veldhuis Kroeze, J.B. and van der Kolk, J.H. (2004) Idiopathic muscular hypertrophy of the oesophagus in the horse: a retrospective study of 31 cases. *Equine vet. J.* **36**, 46-50.
- Cantù, P., Bozzani, A. and Penagini, R. (2003) Spontaneous perforation of an oesophageal diverticulum in achalasia. *Dig. Liver Dis.* **35**, 735-737.
- Costantini, M., Zaninotto, G., Rizzetto, C., Narne, S. and Ancona, E. (2004) Oesophageal diverticula. *Best Pract. Res. Clin. Gastroenterol.* **18**, 3-17.
- Craig, D.R., Shivy, D.R., Pankowski, R.L. and Erb, H.N. (1989) Oesophageal disorders in 61 horses. Results of nonsurgical and surgical management. *Vet. Surg.* **18**, 432-438.
- de Vlieghe, S., Laureyns, J., Hoflack, G., Beeckman, D., Opsomer, G. and de Kruif, A. (2001) Een geval van een fataal verloopende pleuritis veroorzaakt door een slokdarmdivertikel bij een vaars. (A case of fatal pleuritis caused by an oesophageal diverticulum in a cow.) *Vlaams Diergeneeskd. Tijdsch.* **70**, 405-407.
- Dechant, J.E., MacDonald, D.G., Crawford, W.H. and O'Connor, B.P. (1998) Pleuritis associated with perforation of an isolated oesophageal ulcer in a horse. *Equine vet. J.* **30**, 170-172.
- Feige, K., Schwarzwald, C., Fürst, A. and Kaser-Hotz, B. (2000) Oesophageal obstruction in horses: a retrospective study of 34 cases. *Can. vet. J.* **41**, 207-210.
- Ford, T.S., Schumacher, J., Chaffin, M.K., Vacek, J., Brumbaugh, G.W. and Crossland, L.E. (1991) Surgical repair of an intrathoracic oesophageal pulsion diverticulum in a horse. *Vet. Surg.* **20**, 316-319.
- Frauenfelder, H.C. and Adams, S.B. (1982) Oesophageal diverticulectomy in a horse. *J. Am. vet. med. Ass.* **180**, 771-772.
- Fubini, S.L. (2002) Esophageal diseases. In: *Manual of Equine Gastroenterology*, Ed: T. Mair, T. Divers and N. Ducharme, WB Saunders, London. pp 89-96.
- Hackett, R.P., Dyer, R.M. and Hoffer, R.E. (1978) Surgical correction of oesophageal diverticulum in a horse. *J. Am. vet. med. Ass.* **173**, 998-1000.
- Harrison, I.W. and Cartee, R.E. (1990) Surgical correction of a traumatic oesophageal diverticulum in a horse. *Cornell Vet.* **80**, 279-284.
- Hill, A.G., Tiu, A.T. and Martin, I.G. (2003) Boerhaave's syndrome: 10 years experience and review of the literature. *A. N. Z. J. Surg.* **73**, 1008-1010.
- MacDonald, M.H., Richardson, D.W. and Morse, C.C. (1987) Oesophageal phytobezoar in a horse. *J. Am. vet. med. Ass.* **191**, 1455-1456.
- Moore, J.N. and Barton, M.H. (2003) Treatment of endotoxemia. *Vet. Clin. N. Am.: Equine Pract.* **19**, 681-695.
- Murray, R.C. and Gaughan, E.M. (1993) Pulsion diverticulum of the cranial cervical oesophagus in a horse. *Can. vet. J.* **34**, 365-367.
- Nehra, D., Lord, R., DeMeester, T.R., Theisen, J., Peters, J.H., Crookes, P.F. and Bremner, C.G. (2002) Physiologic basis for the treatment of epiphrenic diverticulum. *Ann. Surg.* **235**, 346-354.
- Nutter, K.M. and Ball, O.G. (2004) Oesophageal diverticula: Current classification and important complications. *J. Miss. State Med. Assoc.* **45**, 131-135.
- Stick, J.A. (1999) Diseases of the oesophagus. In: *Equine Medicine and Surgery*, 5th edn., Eds: P.T. Colahan, I.G. Mayhew, A.M. Merritt, and J.N. Moore, Mosby, St Louis. pp 688-689.
- Swain, J.M., McGorum, B.C., Scudamore, C.L. and Pirie, R.S. (2004) Persistent oesophageal obstruction (choke) associated with a diverticulum of the terminal oesophagus in a pony. *Equine vet. Educ.* **6**, 251-254.
- Tedesco, P., Fisichella, P.M., Way, L.W. and Patti, M.G. (2005) Cause and treatment of epiphrenic diverticula. *Am. J. Surg.* **190**, 891-894.
- van Wuijckhuise-Sjouke, L.A. (1983) A pony with 'false' colic. *Tijdschr. Diergeneeskd.* **108**, 67-69.
- Vogel, S.B., Rout, W.R., Martin, T.D. and Abbitt, P.L. (2005) Oesophageal perforation in adults. Aggressive, conservative treatment lowers morbidity and mortality. *Ann. Surg.* **241**, 1016-1023.
- Vrins, A., O'Brien, T.R. and Carlson, G. (1983) Diverticulum and fistula of the lower cervical oesophagus in a horse. *Can. vet. J.* **24**, 385-387.