

# Case Report

## Renal carcinoma as a cause of sudden death in an aged horse

E. J. KNOWLES\*, J. M. WITHERS, M. J. DAY<sup>†</sup> AND T. S. MAIR

*Bell Equine Veterinary Clinic, Butchers Lane, Mereworth, Kent ME18 5GS; and <sup>†</sup>Langford Veterinary Diagnostics, School of Clinical Veterinary Science, Langford, Bristol BS40 5DU, UK.*

**Keywords:** horse; renal carcinoma; tumour; sudden death

### Summary

**This report describes rupture of a primary renal carcinoma as a cause of sudden death of an aged horse that presented with mild clinical signs of colic. The case is considered in the context of the few reported cases in the veterinary literature. The most striking feature of this case was the absence of prodromal signs prior to a catastrophic rupture of the tumour during a diagnostic work-up.**

### Introduction

Renal neoplasia is rare in the horse and the presenting signs are varied and frequently nonspecific. Several types of renal tumour have been reported including nephroblastoma, transitional cell carcinoma and squamous cell carcinoma, although renal cell carcinomas are the most common (Schott 2004). Eighteen cases have been reported in detail in the veterinary literature since 1980. These reports illustrate the diagnostic challenge of this condition, in particular the nonspecific nature of the presenting signs and the tendency for the tumour to remain unnoticed until well advanced.

### Case details

#### History

A 23-year-old Thoroughbred cross gelding was referred to Bell Equine Veterinary Clinic for investigation of colic of around 8 hours' duration. The horse had appeared normal that morning and was seen grazing normally during the day. There was no history of recent medical problems or any management changes, although the horse had received long-term treatment with phenylbutazone (Equipalazone)<sup>1</sup> for osteoarthritis at 2 mg/kg bwt *per os* s.i.d. Mild clinical signs of

colic were seen when the horse was brought in from grazing; these were unresponsive to 4 mg/kg bwt phenylbutazone (Equipalazone) given orally. The referring veterinary surgeon examined the gelding, but the signs of mild discomfort persisted despite further medical treatment with detomidine hydrochloride (Equimidine)<sup>2</sup>, and butylscopolamine bromide with metamizole (Buscopan Compositum)<sup>3</sup>. The gelding was then referred for further evaluation.

#### Clinical examination

On admission the gelding was in good bodily condition, showed no signs of pain and was alert and reactive. He walked normally from the trailer but appeared weak. Initially the gelding was sweating profusely but this reduced after travelling rugs were removed. The heart rate was 50 beats/min and mucous membranes were slightly pale but peripheral pulse quality was normal and the extremities were warm. Rectal temperature and respiratory rate were normal. Gut sounds were present in all quadrants but slightly reduced compared with normal. On rectal palpation there was a large mass of gelatinous consistency in the left dorsal quadrant in the region of the left kidney, and the caudal abdomen felt unusually empty. A nasogastric tube was passed but no reflux was obtained.

Routine haematological and serum biochemical examinations revealed no abnormalities other than elevated glucose (8.9 mmol/l; reference range 2.6–6.5 mmol/l) and glutamate dehydrogenase (GLDH) (24.2 u/l; reference range 1.0–12.0 u/l).

A transabdominal ultrasound examination was started but not completed due to a rapid deterioration in the gelding's condition. Initial findings showed normal small intestinal motility with no distension and normal intestinal wall thickness. There was no increase in peritoneal fluid. At this point the examination was stopped as the gelding suddenly became weaker and began staggering. His mucous membranes became very pale and he became ataxic, collapsed and began thrashing. Romifidine hydrochloride (Sedivet)<sup>3</sup> was

\*Author to whom correspondence should be addressed.

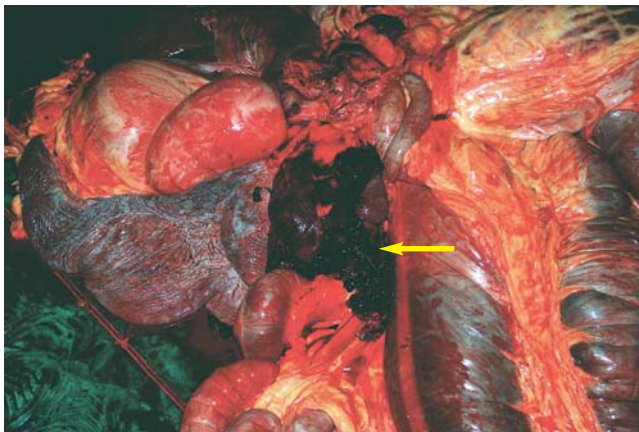
administered i.v. at 0.08 mg/kg bwt to provide sedation in an attempt to insert an i.v. catheter but this proved impossible and the gelding died after a few minutes.

### Post mortem examination

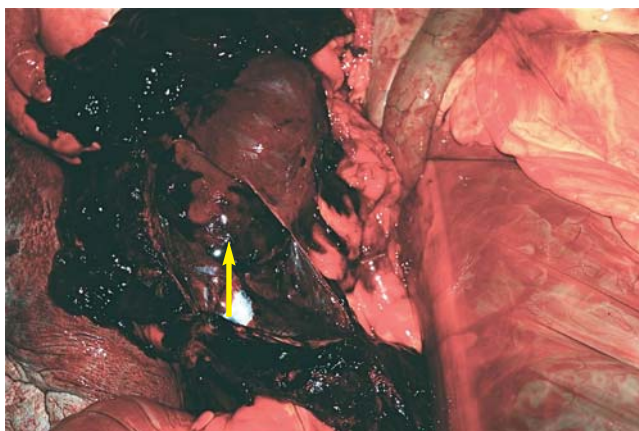
*Post mortem* examination was performed within 30 min of death and revealed rupture of the caudal pole of the left kidney. This was markedly enlarged and gelatinous (Figs 1 and 2). There was extensive intra-abdominal haemorrhage and a number of unidentifiable friable masses were found free within the abdominal cavity. Grossly there were no signs of metastatic spread to any other organs. There was also a 180° torsion of the large colon close to the diaphragmatic and sternal flexures, but no visible signs of colonic distension or damage to the colon wall. The significance of this torsion is unclear.

### Histopathology

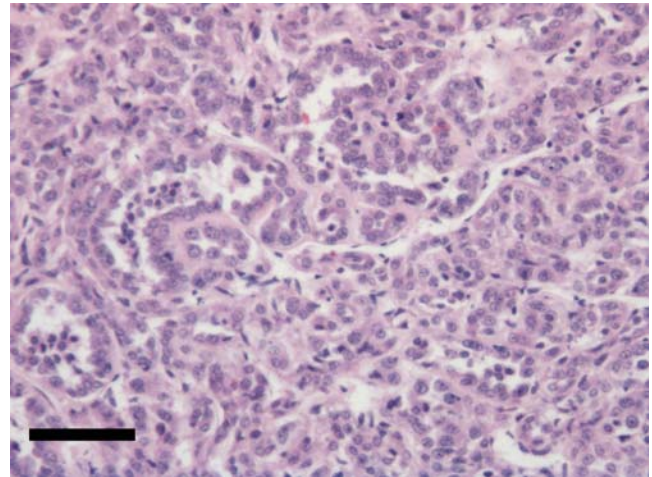
Histopathological examination of several samples from the left kidney revealed a large area of neoplastic change consistent with renal carcinoma (Fig 3). The tumour was separated from



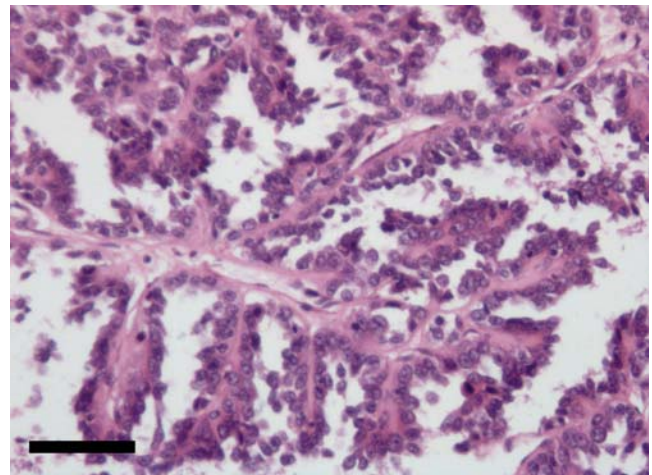
**Fig 1:** Post mortem abdominal viscera showing a large volume of clotted blood (yellow arrow) from the ruptured caudal pole of the left kidney.



**Fig 2:** Post mortem abdominal viscera showing the ruptured caudal pole of the left kidney (yellow arrow).



**Fig 3:** Photomicrograph from the main renal lesion showing neoplastic cells arranged in irregular acinar structures lined by cuboidal epithelium. Bar: 100 µm.



**Fig 4:** Photomicrograph of a histological section of one of the friable masses found free in the abdomen. The tissue has a papillary appearance with branching septae lined by cuboidal epithelium. The cavities are filled with blood and proteinaceous material. Bar: 100 µm.

areas of normal kidney by a fibrous band but there were numerous small clusters of neoplastic cells distant from the main tumour in the junctional margin. Further samples of the tumour showed areas of haemorrhage with prominent haemosiderophages and sub-capsular blood clots. There were further areas of largely fibrotic kidney with minimal remaining tubular architecture. Samples of the cranial pole of the left kidney were normal.

The unidentifiable friable masses lying free within the abdomen appeared to be sections of the renal tumour with neoplastic changes, and areas of haemorrhage and necrosis. The histological appearance of these was consistent with acute rupture of these masses from the main tumour (Fig 4). The right kidney was structurally normal and the liver and spleen had prominent haemosiderosis but normal architecture. Histologically there were no signs of metastatic spread.

## Discussion

Renal carcinoma is a rare condition in the horse. The incidences of primary renal neoplasia and renal carcinoma have been reported as 0.11% and 0.055%, respectively (Haschek *et al.* 1980). Published reports highlight the variable and nonspecific presentations and clinical signs of this condition. The sudden death of this gelding is a stark reminder of the diagnostic challenges presented by renal carcinomas and by abdominal tumours in general, and of their tendency to present at an advanced stage of disease (East and Savage 1998; Schott 2004).

A search of the veterinary literature since 1980 revealed 22 cases of equine renal carcinoma, although only 18 have been described in detail (Berggren 1980; Haschek *et al.* 1981; Pomroy 1981; Brown and Holt 1984; van Amstel *et al.* 1984; Owen *et al.* 1986; Servantie *et al.* 1986; van Mol and Franssen 1986; West *et al.* 1987; Rhind *et al.* 1989; Baker *et al.* 2001; Rumbaugh *et al.* 2003; Swain *et al.* 2005; Hilton *et al.* 2008). No breed or sex predispositions are apparent from these cases. The ages of horses affected ranged from 4–21 years and the median age was 14 years.

Clinical signs of equine renal carcinomas are variable: weight loss was reported in 15/18 cases (83%), haematuria in 9/18 (50%) (although results of urinalysis were not recorded in 2 cases) and colic was reported in 7/18 (39%). Human renal carcinoma patients present with a wide variety of signs but many are asymptomatic until the disease is advanced (Olumi and Richie 2004). Many reported cases of equine renal carcinoma presented with signs attributable to the primary tumour but a significant minority presented with complaints resulting from paraneoplastic syndromes or metastasis.

Baker *et al.* (2001) and Swain *et al.* (2005) describe intermittent hypoglycaemia as a paraneoplastic effect of renal carcinomas. This is a well described paraneoplastic syndrome of man and dogs (Leafier *et al.* 1985; Chung *et al.* 1986) and is thought to result from the production of an abnormal form of insulin-like growth factor 2 (IGF-2) (Baxter *et al.* 1995). In the horse paraneoplastic hypoglycaemia has been also described in association with an insulinoma (Ross *et al.* 1983) but is more commonly associated with non-islet hepatocellular carcinomas (Ogilvie 1998). Human renal carcinomas have been associated with a wide range of paraneoplastic syndromes and have consequently been labelled the 'internists tumour' (Gold *et al.* 1996). No paraneoplastic signs were evident in the case described here.

Rhind *et al.* (1999) and Rumbaugh *et al.* (2003) describe cases that presented with signs caused by metastasis (to the oral cavity and elbow respectively) rather than the primary tumour. Unusually, the present case showed no evidence of metastasis. Reports suggest that metastasis of equine renal carcinoma occurs commonly and was grossly evident at *post mortem* examination in 13/18 cases (72%). Sites for metastasis varied but most frequently involved the liver and lungs.

In contrast to previously reported cases, this case presented with mild clinical signs of colic of only a few hours'

duration. The authors consider that these were likely to have been caused by sub-capsular bleeding from the renal tumour. In the absence of distension or colonic wall damage, the mild colon torsion identified *post mortem* was considered unlikely to have been clinically significant. No other prodromal signs were recognised. There is only one previous report of renal carcinoma causing death without prodromal signs. A Thoroughbred gelding died during recovery from anaesthesia for laryngeal surgery as a result of compression of the caudal vena cava by the tumour (Robertson *et al.* 1985).

The case described here also had no significant abnormalities on haematological or serum biochemical evaluation. Most reports describe nonspecific haematological abnormalities, most frequently leucocytosis due to neutrophilia (9/18 cases). Serum urea and creatinine are often normal in cases of renal carcinoma due to the reserve functional capacity provided by the contralateral kidney. The condition is usually unilateral with just 3 reported cases of bilateral renal carcinoma in the horse (Berggren 1980; West *et al.* 1987; Rhind *et al.* 1999).

Whilst this case emphasises the diagnostic challenge presented by renal carcinomas, the sudden deterioration and death of this gelding prevented the completion of the diagnostic work-up. In common with 12 of the 18 previously reported cases (67%), a mass was palpable *per rectum* and, had time allowed, further diagnostic aids would have been used.

Transabdominal or transrectal ultrasonography may have allowed visualisation of the mass and ultrasound guided biopsies could have been obtained (although this would have carried a substantial risk). More recently, intra-abdominal renal ultrasonography has been performed via standing flank laparotomy prior to nephrectomy (Ferguson *et al.* 2007).

Haemoperitoneum may also be diagnosed ultrasonographically and is characterised by swirling hypo-echogenic, cellular fluid (Dechant *et al.* 2006). In this case haemoperitoneum was not identified *ante mortem*. It appears that the initial haemorrhage occurred beneath the renal or tumour capsule or was contained within the retroperitoneal space. Profuse abdominal haemorrhage only occurred when the tumour ruptured, perhaps precipitated by rectal palpation of the mass, despite the cautious approach of the examiner.

Abdominocentesis is a further diagnostic aid that may be employed in the assessment of colic and diagnosis of abdominal neoplasia. The presence of neoplastic cells in peritoneal fluid is a highly specific but insensitive indicator of abdominal neoplasia. In only 11/25 (44%) horses with intra-abdominal neoplasia were tumour cells identified by cytological examination of peritoneal fluid in a study by Zicker *et al.* (1990).

The outcome for equine renal carcinoma is universally poor but sudden death through acute haemorrhage is an unusual outcome. Brown and Holt (1984) also describe death due to haemorrhage from a renal carcinoma but unlike this case there was a history of chronic weight loss, depressed appetite, colic, polyuria and polydipsia. Most

reported cases died or were subjected to euthanasia shortly after diagnosis, with 2 notable exceptions. Owen *et al.* (1986) describe a Shire mare in which the course of the disease and associated hypercupraemia were followed for 11 months before euthanasia was necessary. Hilton *et al.* (2008) reported a 7 month survival time following a hand-assisted laparoscopic nephrectomy. No metastases were evident at the time of laparoscopy but the gelding was subjected to euthanasia 7 months later due to multifocal carcinomatosis. Ferguson *et al.* (2007) successfully treated a renal papillary adenoma in a Thoroughbred gelding by a similar technique. Theoretically, the current case could have been a candidate for such a procedure as no metastatic spread was evident grossly. This would have required much earlier diagnosis, but in this case, an earlier diagnosis (particularly if made on histological grounds) would probably have led to a recommendation of euthanasia due to the high metastatic rate attributed to renal carcinomas.

In conclusion, the present case illustrates the variation, and in some cases paucity, of clinical signs caused by renal carcinomas. In common with many other abdominal tumours, renal carcinomas may show no signs until very well advanced. In contrast to other reports this carcinoma showed no evidence of metastasis and could thus have been a potential candidate for unilateral nephrectomy. The *ante mortem* detection of metastasis can be extremely difficult and thus nephrectomy cannot be recommended for the majority of renal carcinomas.

## Manufacturers' addresses

<sup>1</sup>Dechra Veterinary Products, Shrewsbury, Shropshire, UK.

<sup>2</sup>Fort Dodge Animal Health, Southampton, Hampshire, UK.

<sup>3</sup>Boehringer Ingelheim Ltd, Bracknell, Berkshire, UK.

## References

- Baker, J.L., Aleman, M. and Madigan, J. (2001) Intermittent hypoglycaemia in a horse with anaplastic carcinoma of the kidney. *J. Am. vet. med. Ass.* **218**, 235-237.
- Baxter, R.C., Holman, S.R., Corbould, A., Stranks, S., Ho, P.J. and Braund, W. (1995) Regulation of the insulin-like growth factors and their binding proteins by glucocorticoid and growth hormone in non islet cell tumour hypoglycaemia. *J. clin. Endocrinol. Metabol.* **80**, 2700-2708.
- Berggren, P.C. (1980) Renal adenocarcinoma in a horse. *J. Am. vet. med. Ass.* **176**, 1252-1253.
- Brown, P.J. and Holt, P.E. (1985) Primary renal cell carcinoma in four horses. *Equine vet. J.* **17**, 473-477.
- Chung, J. and Henry, R.R. (1996) Mechanisms of tumour-induced hypoglycaemia with intra-abdominal hemangiopericytoma. *J. clin. Endocrinol. Metabol.* **81**, 919-925.
- Dechant, J.E., Nieto, J.E. and Le Jeune, S.S. (2006) Haemoperitoneum in horses: 67 cases (1989-2004). *J. Am. vet. med. Ass.* **229**, 253-258.
- East, L.M. and Savage, C.J. (1998) Abdominal neoplasia. *Vet. Clin. N. Am.: Equine Pract.* **14**, 475-495.
- Ferguson, N., Couetil, L., Hawkins, J., Ernst, C., Sojka, J. and van Alstine, W. (2007) Unilateral nephrectomy in two aged horses. *Equine vet. Educ.* **19**, 300-305.
- Gold, P.J., Fefer, A. and Thompson, J.A. (1996) Paraneoplastic manifestations of renal cell carcinoma. *Semin. Urol. Oncol.* **14**, 216-222.
- Haschek, W.M., King, J.M. and Tennett, B.C. (1981) Primary renal carcinoma in two horses. *J. Am. vet. med. Ass.* **179**, 992-994.
- Hilton, H.G., Aleman, M., Maher, O., Peterson, T.S., Whitcomb, M.B. and Galuppo, L.D. (2008) Hand-assisted laparoscopic nephrectomy in a standing horse for the management of renal cell carcinoma. *Equine vet. Educ.* **20**, 239-244.
- Ogilvie, G.K. (1998) Paraneoplastic syndromes. *Vet. Clin. N. Am.: Equine Pract.* **14**, 439-449.
- Olumi, A.F. and Richie, J.P. (2004) Urologic surgery. In: *Sabiston Textbook of Surgery*, 17th edn., Eds: C.M. Townsend, R.D. Beachamp, M.B. Evers and K.L. Mattox, Elsevier, Philadelphia. pp 2305-2306.
- Owen, R.R., Haywood, S. and Kelly, D.F. (1986) Clinical course of renal adenocarcinoma associated with hypercupraemia in a horse. *Vet. Rec.* **119**, 291-294.
- Pomroy, W. (1981) Renal adenocarcinoma in a horse. *Equine vet. J.* **13**, 198-199.
- Leafier, C.E., Peterson, M.E., Mattus, R.E. and Patnaik, A.K. (1985) Hypoglycaemia associated with non-islet cell tumour in 13 dogs. *J. Am. vet. med. Ass.* **186**, 53-55.
- Rhind, S.M., Hawe, C., Dixon, P.M. and Scudamore, C.L. (1999) Oral metastasis of renal cell carcinoma in a horse. *J. comp. Pathol.* **120**, 97-103.
- Robertson, S.A., Waterman, A.E., Lane, J.G. and Brown, P.J. (1985) An unusual cause of anaesthetic death in a horse. *Equine vet. J.* **17**, 403-404.
- Ross, M.W., Lowe, J.E., Cooper, B.J., Reimers, T.J. and Froscher, B.A. (1983) Hypoglycemic seizures in a Shetland pony. *Cornell Vet.* **73**, 151-169.
- Rumbaugh, M.L., Latimer, F.G., Porthouse, K.P., Cho, D.Y. and Leblanc, C.J. (2003) Renal carcinoma with osseous and pulmonary metastases in an Arabian gelding. *Equine vet. J.* **35**, 107-109.
- Servantie, J., Magnol, J.P., Regnier, A., Lescure, F. and Merritt, A.M. (1986) Carcinoma of the renal pelvis with bony metaplasia in a horse. *Equine vet. J.* **18**, 236-238.
- Schott, H.C. (2004) Neoplasia of the urinary tract. In: *Equine Internal Medicine*, 2nd edn., Eds: S.M. Reed, W.M. Bayly and D.C. Sellon, Saunders Elsevier, St Louis. pp 1287-1289.
- Swain, J.M., Pirie, R.S., Hudson, N.P.H., Else, R.W., Evans, H. and McGorum, B.C. (2005) Insulin-like growth factors and recurrent hypoglycemia associated with renal cell carcinoma in a horse. *J. vet. intern. Med.* **19**, 613-616.
- van Amstel, S.R., Huchzermeyer, D. and Reyers, F. (1984) Primary renal cell carcinoma in a horse. *J. S. Afr. vet. Ass.* **55**, 35-38.
- van Mol, K.A.C. and Fransen, J.L.A. (1986) Renal carcinoma in a horse. *Vet. Rec.* **119**, 238-239.
- West, H.J., Kelly, D.F. and Ritchie, H.E. (1987) Renalcarcinomatosis in a horse. *Equine vet. J.* **19**, 548-551.
- Zicker, S.C., Wilson, W.D. and Medearis, I. (1990) Differentiation between intra-abdominal neoplasms and abscesses in horses, using clinical and laboratory data: 40 cases (1973-1988). *J. Am. vet. med. Ass.* **196**, 1130-1134.