

# Case Report

## Congenital limb abnormality in a Thoroughbred foal in Trinidad

K. A. Muñoz\* and D. K. Coombs

Faculty of Medical Sciences, School of Veterinary Medicine, The University of the West Indies, Trinidad and Tobago, West Indies.

**Keywords:** horse; hoof; pathology; hindlimb digits; congenital

### Summary

**A congenital defect of the right hindlimb of a 36-h-old Thoroughbred foal as reported for the first time in Trinidad, West Indies. The foal was subjected to euthanasia and radiographs of both hindlimbs revealed that the bones distal to P1 of the right hindlimb only, were missing. Insertion of both the superficial and deep digital flexor tendons were found to be on the most proximal aspect of P1. Necropsy revealed no other congenital defects.**

### Introduction

The condition adactylism is a congenital malformation characterised by the absence of toes and seems to be very uncommon in the horse, and very little literature is available on this condition. Polydactylism, however, has been reported to be a common congenital defect in the foal (Theile 1958).

### Case details

#### History

A 36-h-old colt foal was presented for a defect of the distal aspect of its right hindlimb. The owner had reported that the colt was born missing the distal aspect of its right hindlimb from the fetlock down and that there appeared to be a small amount of hoof tissue at the end of the digit. The birth had not been observed but was estimated to be within 1 h of discovery based on the foal being still damp from amniotic secretions and that the third stage of labour was not yet completed. Over the next few hours the foal was noted to be nursing normally from the mare and moving around well despite his abnormality. However, the owner bandaged the lesion to protect against potential

trauma from the ground (**Fig 1**). In addition, the owner noted that the meconium was passed normally and no other problems were detected besides the abnormal limb. The mare was a 19-year-old broodmare who had produced 5 foals prior to this one with no reported abnormalities in her offspring. She previously had difficulty conceiving in some years with no history of endometritis.

### Clinical findings

On inspection the foal had no other obvious gross abnormalities and appeared normally proportioned for his age. He had a body condition score of 2.5/5. On physical examination, cardiac and pulmonary auscultations were normal. In addition no cleft palate, hernias or ocular lesions were identified, and the limbs showed no evidence of angular limb deformities. Flexion and extension of all 4 limbs were also noted to be within normal limits. However, on the right hindlimb, the digit appeared to end in a stump suspended 6–8 cm above the ground. On removing the bandage the stump was observed to be surrounded by hair with a hyperaemic soft tissue covering on the solar aspect ending just below the



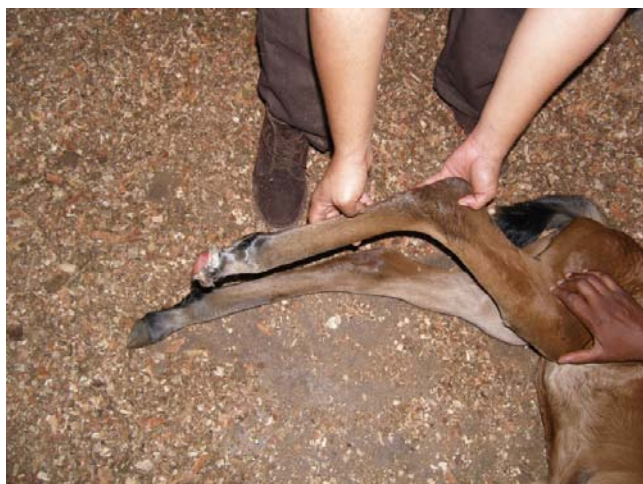**Fig 1:** Foal with distal aspect of right hindlimb bandaged.

\*Author to whom correspondence should be addressed.

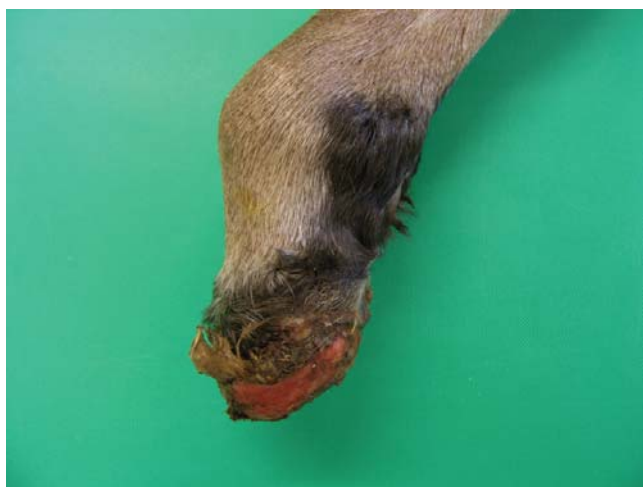fetlock. From this examination it appeared that the distal part of the foot and hoof wall were absent (**Figs 2 and 3**). No keratinised hoof tissue was observed at the end of the digit. Due to the severity of the congenital limb abnormality, the prospect for racing was considered to be hopeless and it was therefore decided to subject the foal to euthanasia.

### Post mortem findings

With the exception of the affected limb, no gross abnormalities or congenital defects were identified on routine *post mortem* examination. Radiographs were taken of both hindlimbs from the stifle distally for comparison. The left hindlimb appeared normal, but the right hindlimb showed no evidence of bones distal to the proximal phalanx (P1). There was a small unidentified structure with the radiopacity of bone just distal to P1 (**Fig 4**) but there was no hoof wall present. On further examination of this radiopaque structure, it was found to



**Fig 2: Abnormal right hindlimb.**



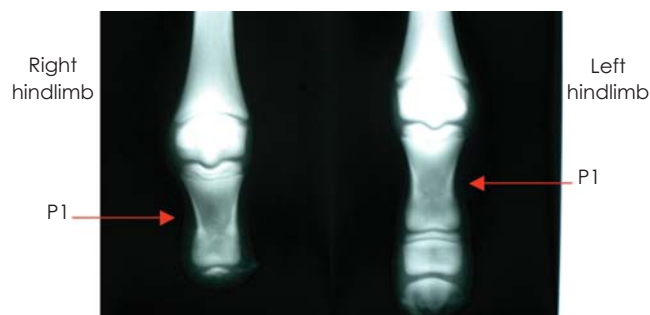
**Fig 3: Close-up view of the limb in Figure 2.**

be cartilage and, according to the pathologist, histological examination of this structure would have revealed no further information.

Careful dissection of the right hindlimb showed that the middle (P2) and distal (P3) phalanges were absent. The proximal phalanx (P1) appeared shorter and smaller in diameter with some cortical thickening in comparison with the contralateral phalanx. Both the superficial and deep digital flexor tendons were found to be inserting at the same area on the distal end of P1.

### Discussion

Embryologically, at around 4 weeks of development, the limbs develop from an outgrowth of mesenchyme covered with ectoderm, at 4 distinct sites called limb buds. As the limb bud grows, condensation of the mesenchyme occurs, resulting in digital blastema, which represents the future digits of the limb. Definitive digits form as the tissue between the digital condensations degenerates, leaving each digit as a separate individual unit (Noden and de Lahunta 1985; Latshaw 1987). In a study performed by Crowe and Swerczek (1985), the following congenital anomalies were observed: contracted foal syndrome (33.2%), miscellaneous limb contraction (20%), multiple defects (5.3%), microphthalmia (4.6%), craniofacial malformations (4.3%), cleft palate (4.0%), heart defects (3.5%), umbilical defects (3.5%) and hydrocephalus (3.0%). Eleven less frequently occurring anomalies constituted the balance of the congenital defects in fetuses and newborn foals (Hardy and Latimer 2003). Leipold *et al.* (1971) reported a case of agenesis of all the bones distal to the radius except one carpal bone with concomitant forelimb polydactyly. It is uncommon, however, to find congenital malformation of the phalanges in horses as well as in other species (Huston *et al.* 1977; Bertone and Aanes 1984). In a study by Smith *et al.* (1986) abnormalities were found in both hindlimbs of a 7-month-old Appaloosa foal, in which the right hind leg resembled that of a fetus of about 120 days gestation. Phalangeal and navicular hypoplasia was evident, however, as in this case the aetiology of the defects was not known. Theories put forward were that of a teratogenic effect of some drug or substance within the environment of the animal and heritability as well as



**Fig 4: Radiographs of both hindlimbs.**

acquired defects (Barber 1990). It has been reported that congenital defects of the appendicular skeleton do occur sporadically, thus limiting the ability to determine the aetiology of these conditions. Phalangeal anomalies have been reported with clinical abnormalities such as hoof defects as well as hoof deviations all being evident at birth (Reeves *et al.* 1989; Riley *et al.* 1990). While some of the more common congenital defects have been seen in Trinidad, this defect has never been reported here before. The presentation of this case is unusual as one would expect a congenital abnormality to affect limbs bilaterally or all 4 together. It is unlikely that this case was the result of *peripartum* trauma due to the gross appearance of the leg, and the insertion of both superficial and deep digital flexor tendons on the distal aspect of P1 and on the radiographs. If trauma was the cause of this injury some shearing of the soft tissue around the stump would have been expected to have been present.

## References

- Barber, S.M. (1990) Unusual polydactylism in a foal: a case report. *Vet Surg.* **19**, 203-207.
- Bertone, A.L. and Aanes, W.A. (1984) Congenital phalangeal hypoplasia in *Equidae*. *J. Am. vet. med. Ass.* **185**, 554-556.
- Crowe, M.W. and Swerczek, T.W. (1985) Equine congenital defects. *Am. J. vet. Res.* **46**, 353-358.
- Hardy, J. and Latimer, F. (2003) Orthopedic disorders in the neonatal foal. *Clin. Tech. equine Pract.* **2**, 96-119.
- Huston, R., Saperstein, G. and Leipold, H.W. (1977) Congenital defects in foals. *J. equine med. Surg.* **1**, 146-161.
- Latshaw, W.K. (1987) *Veterinary Developmental Anatomy: A Clinically Oriented Approach*, Ed: W.K. Latshaw, B.C. De Decker, Toronto. pp 128-129.
- Noden, D.M. and de Lahunta, A. (1985) *The Embryology of Domestic Animals: Developmental Mechanisms and Malformations*. Williams and Wilkins, Baltimore. pp 196-197.
- Reeves, M.J., Yovich, J.V. and Turner, A.S. (1989) Miscellaneous conditions of the equine. *Vet. Clin. N. Am.: Equine Pract.* **5**, 221-242.
- Riley, C.B., Yovich, J.V. and Huxtable, C.R. (1990) A phalangeal fusion defect and osteochondrosis dissecans with subluxation of the distal interphalangeal joints in a foal. *Aust. vet. J.* **67**, 331-333.
- Smith, D.R.K., Leach, D.H. and Bell, R.J. (1986) Phalangeal and navicular bone hypoplasia and hoof malformation in the hind limbs of a foal. *Can. vet. J.* **27**, 28-30, 31-40.
- Theile, H. (1958) Polydactylism in a foal. *Monatsh. Veterinaermed.* **13**, 342.