

Retrospective study of palmar/plantar annular ligament injury in 71 horses: 2001–2006

K. R. OWEN, S. J. DYSON*, T. D. H. PARKIN†, E. R. SINGER†, M. KRISTOFFERSEN† and T. S. MAIR§

Centre for Equine Studies, Animal Health Trust, Newmarket, Suffolk; †University of Glasgow Veterinary School, Bearsden Road, Glasgow; ‡Philip Leverhulme Large Animal Hospital, Leahurst, Neston, Cheshire; and §Bell Equine Veterinary Clinic, Kent, UK.

Keywords: horse; lameness; fetlock; desmopathy; ultrasonography; desmotomy; tenoscopy

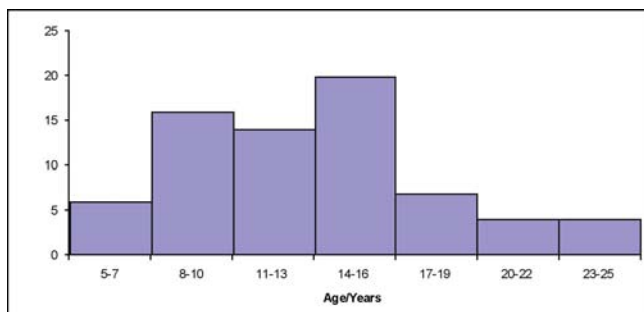


Fig o1: A histogram of age distribution of 71 horses with palmar/plantar annular ligament injury.

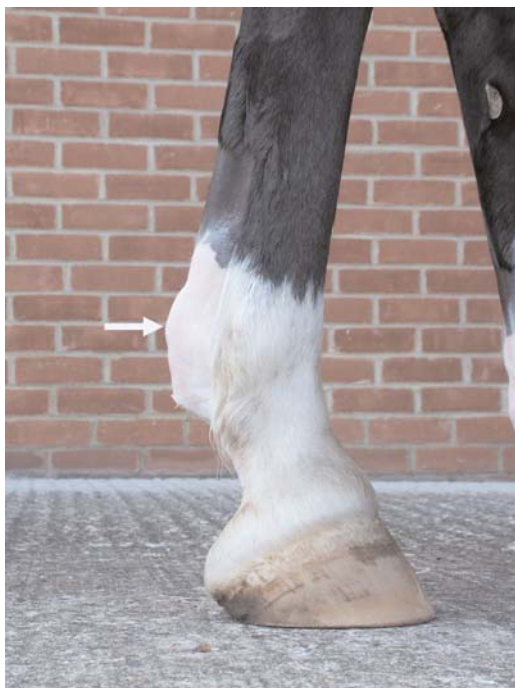

Fig o2: Lateral view of the right hindlimb of a 15-year-old pony with acute onset severe right hindlimb lameness of 6 weeks' duration (same pony as in Figs o3, o6, o7 and o8). The distal limb has been clipped which reveals a clear convex appearance of the plantar aspect of the fetlock (white arrow), representing thickening of the plantar annular ligament (PAL), with the digital flexor tendon sheath bulging proximally to the PAL. There was localised heat and consistent exacerbation of lameness by distal limb flexion.

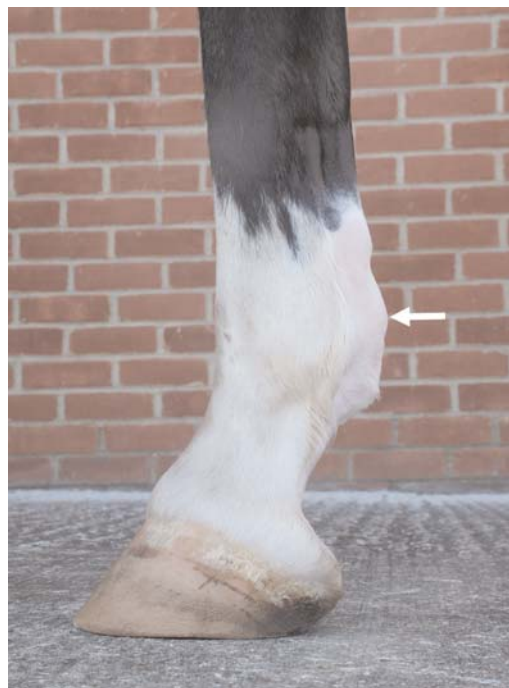

Fig o3: Lateral view of the left hindlimb of a 15-year-old pony with right hindlimb lameness (same as in Figs o2, o6, o7). There is soft tissue swelling on the plantar aspect of the fetlock (white arrow), but less than in the right hindlimb (Fig o2). There was no response to distal limb flexion of the left hindlimb. Right hindlimb lameness was abolished by perineural analgesia of the plantar nerves proximal to the digital flexor tendon sheath and the plantar metatarsal nerves. There was no evidence of left hindlimb lameness.

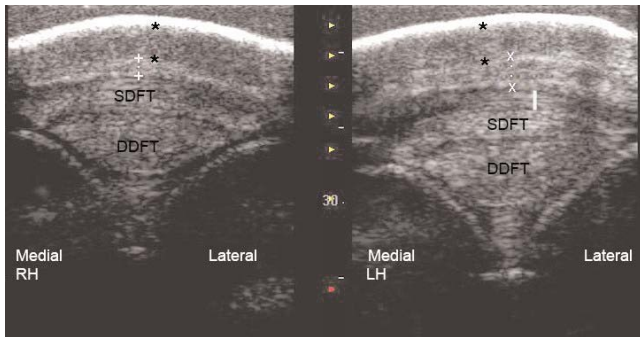


Fig o4: Transverse bilateral ultrasonographic images of the plantar fetlock regions of a 14-year-old pony. In the right hind (RH) image the PAL is thickened (X to X, 4.15 mm) and has loss of fibre pattern compared to the normal ultrasonographic appearance of the left hind (LH) (+ to +, 1.55 mm). Thickening of the DFTS (Digital flexor tendon sheath) is also present in the LH (solid white line). Skin thickness is similar in both limbs (* to *). The relative hypoechoic band to the right of the images reflects a contact artefact. SDFT = Superficial digital flexor tendon; DDFT = deep digital flexor tendon.

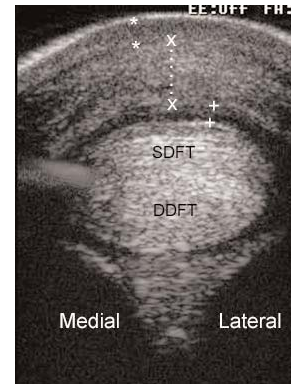


Fig o6: Transverse ultrasonographic view at the level of the plantar aspect of the right hind fetlock of a 15-year-old pony. There is severe thickening of the plantar annular ligament (X to X, 7.91 mm). There is mild thickening of the digital flexor tendon sheath (DFTS) and anechogenic fluid accumulation within the sheath (+ to +). There is an ill-defined, horizontal echogenic area at the medial aspect of the SDFT reflecting an artefact. (Skin * to *). SDFT = Superficial digital flexor tendon; DDFT = deep digital flexor tendon.

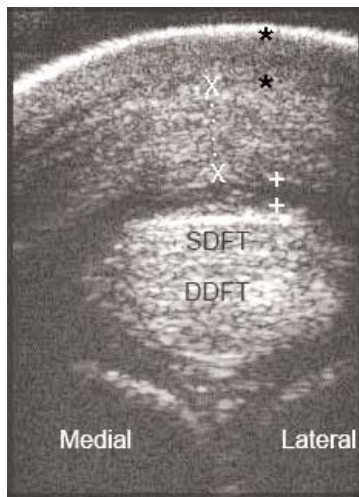


Fig o5: Transverse ultrasonographic view at the level of the plantar aspect of the fetlock region of a 9-year-old pony. The plantar annular ligament (PAL) is severely thickened (X to X, 10.11 mm). There is anechogenic fluid in the digital flexor tendon sheath (+ to +), reflecting effusion. The convex contour on the plantar aspect of the limb gave a fairly narrow window for examination. Assessment of the more abaxial aspects of the PAL required moving the transducer medially and laterally. (Skin * to *). Superficial digital flexor tendon; DDFT = deep digital flexor tendon.

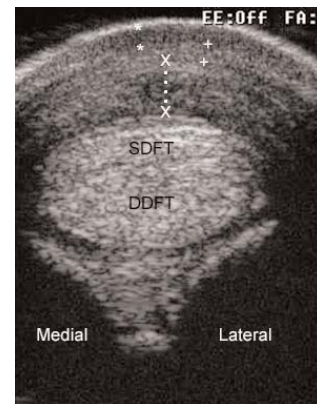


Fig o7: A transverse ultrasonographic image of the left hindlimb of a 15-year-old pony with right hindlimb lameness (same pony as in Figs o2, o3, o6 and o8). The PAL is thickened (X to X, 5.85 mm), but less severely than the lame right hindlimb. The PAL has hypoechoic areas. There is also mild subcutaneous fibrosis, especially laterally (+ to +). Skin (* to *). SDFT = Superficial digital flexor tendon; DDFT = deep digital flexor tendon.

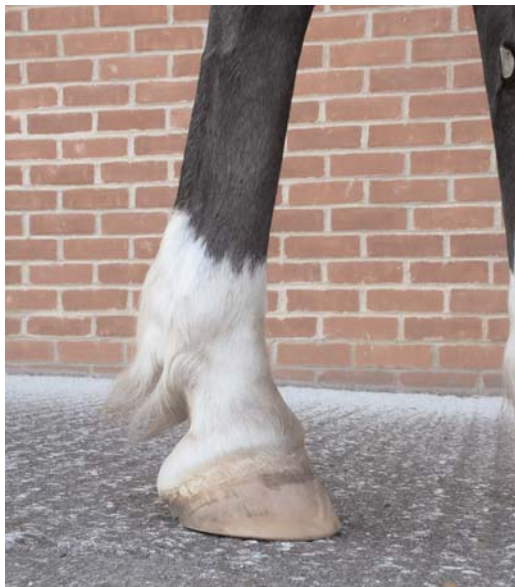

Fig 08: Lateral view of the right hindlimb of a 15-year-old pony with right hindlimb lameness (same as in Figs 02, 06). The leg is unclipped and thickening of the plantar annular ligament (PAL) and associated structures is easily missed by visual appraisal, but was readily palpable.